

Hypertrophic Scars and Keloids

Etiology and Management

Tina S. Alster and Elizabeth L. Tanzi

The Washington Institute of Dermatologic Laser Surgery, Washington, USA

Contents

Abstract	235
1. Definition of Keloid and Hypertrophic Scars	236
2. The Nature of Keloid and Hypertrophic Scars	236
2.1 Etiology	236
2.2 Epidemiology	236
2.3 Clinical Features	237
2.4 Histology	237
3. Pathophysiology	237
3.1 Wound Healing	237
3.2 Pathophysiology	237
4. Treatment of Keloid and Hypertrophic Scars	238
4.1 Surgery	238
4.2 Radiation	238
4.3 Pressure Therapy	238
4.4 Cryotherapy	239
4.5 Silicone Gel Sheeting and Other Dressings	239
4.6 Intralesional Corticosteroids	239
4.7 Interferon	239
4.8 Fluorouracil	239
4.9 Laser	239
4.10 Other Treatments	240
5. Conclusion	240

Abstract

Keloid and hypertrophic scars have affected patients and frustrated physicians for centuries. Keloid and hypertrophic scars result from excessive collagen deposition, the cause of which remains elusive. Clinically, these scars can be disfiguring functionally, aesthetically, or both. A thorough understanding of the pathophysiology and clinical nature of the scar can help define the most appropriate treatment strategy.

Although many articles have been published on the management of hypertrophic and keloid scars, there is no universally accepted treatment protocol. Prevention of keloid and hypertrophic scars remains the best strategy; therefore, those patients with a predisposition to develop excessive scar formation should avoid nonessential surgery. Once a scar is present, there are many treatments from which to choose. Hypertrophic scars and keloids have been shown to respond to radiation, pressure therapy, cryotherapy, intralesional injections of corticosteroid, interferon and fluorouracil, topical silicone or other dressings, and pulsed-dye laser treatment. Simple surgical excision is usually followed by recurrence unless adjunct therapies are employed. Biologic agents that are directed towards the aberrant collagen proliferation that characterizes keloid and hypertrophic scars might be an important addition to the current armamentarium of modalities in the near future.

Despite increased knowledge of wound healing and collagen metabolism in recent years, hypertrophic scars and keloids remain a therapeutic challenge. Keloids have been recognized for centuries.^[1] In 1806, Alibert^[2] used the term 'cheloide' derived from the greek 'chele' meaning crab claw to describe the lateral expansion of an excessive scar into the surrounding normal tissue. Hypertrophic and keloid scars may lead to significant morbidity as well as pruritus, pain, restriction of motion, or cosmetic disfigurement. There is no universally accepted treatment modality resulting in permanent eradication of hypertrophic or keloid scars.

1. Definition of Keloid and Hypertrophic Scars

A clinical definition has often been used to distinguish hypertrophic scars from keloids.^[3,4] Hypertrophic scars remain within the confines of the original wound, whereas keloids extend beyond the boundaries of the skin injury (figure 1 and figure 2).

Hypertrophic scars usually occur shortly after injury (weeks) and may regress with time as compared with keloids which may manifest months to years after the initial injury and do not show a tendency towards regression.^[5,6] One study demonstrated an average of 30.4 months between injury and the development of a keloid.^[7] Others utilize a temporal definition to differentiate the types of scarring, suggesting that a hypertrophic scar that is present for 12 months, with extension beyond the original site of injury, has evolved into a keloid.^[8] Hypertrophic scars may be more responsive to treatment, whereas keloids are often resistant to treatment and have a higher rate of recurrence.^[9]

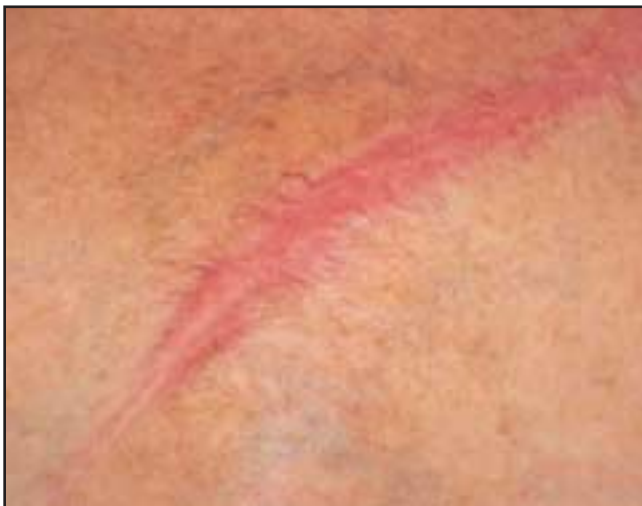

Fig. 1. Typical clinical appearance of a hypertrophic scar.

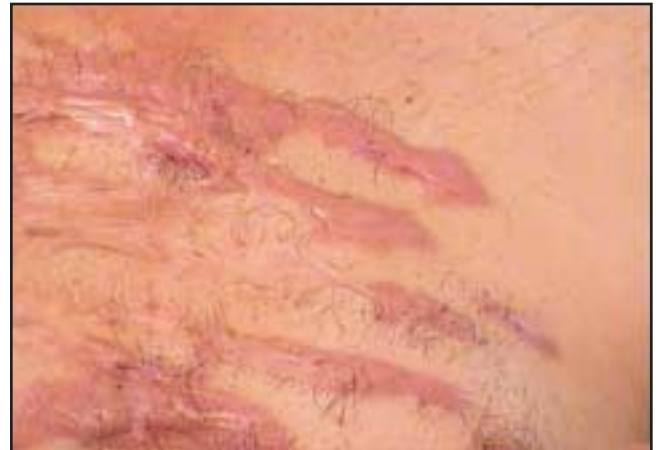

Fig. 2. Typical clinical appearance of a keloid.

2. The Nature of Keloid and Hypertrophic Scars

2.1 Etiology

Various factors including location of injury and ethnic background may predispose a patient to the development of keloid or hypertrophic scars. Several types of skin injury including surgery, piercing, burns, lacerations, abrasions, tattoo placement, vaccinations, insect bites, and any inflammatory process such as acne, varicella, or folliculitis, can induce keloids.^[7,10] Rarely, no antecedent injury can be identified.^[11]

Wound tension has been implicated as a factor in the development of keloid and hypertrophic scar formation.^[12-14] Tension may result from attempts to close a wound in which there has been loss of tissue, underlying bony structures, or mobility over a joint. Although many surgeons stress the importance of minimizing tension across a wound in a patient predisposed to keloid or hypertrophic scarring, no controlled studies have been performed to prove this hypothesis and many studies show high levels of recurrence despite meticulous surgical repair.^[15]

2.2 Epidemiology

Keloids are more common among patients with darker skin phototypes with an incidence of 4.5–16% in the Black and Hispanic populations.^[16-18] Although the frequency of keloid scarring in other ethnic groups is not as well defined, one study evaluated 175 patients of Chinese, Malaysian, and Indian descent and demonstrated a higher incidence of keloids among patients of Chinese descent.^[19]

Keloids occur with equal frequency in men and women.^[20,21] Although hypertrophic and keloid scars can develop at any age, patients between 10 and 30 years old are most often affected.^[3,6] One study found the average age of patients at the time of initial

treatment was 25.8 years with a median onset of approximately 22 years of age in both men and women.^[7] In 14 large pedigrees, Marneros and colleagues^[22] described familial keloids as an autosomal dominant entity with incomplete penetrance and variable expression.

2.3 Clinical Features

Keloids vary in size from a few millimeters in diameter to several centimeters or larger and may be soft and doughy or firm and banded. Areas particularly prone to keloidal scarring include the ears, cheeks, shoulders, chest, upper arms, and upper back.^[23] Some authors feel these areas are more likely to scar due to the increased skin tension in these areas;^[10] however, others have challenged this conclusion.^[24]

In addition to the disfigurement keloid and hypertrophic scars may inflict on patients, they can be complicated by pruritus, tenderness, burning, secondary infection, ulceration, and restriction of motion.^[15,25] One study found pruritus and pain in 27 and 19% of patients, respectively.^[7]

2.4 Histology

Histopathologically, the differentiation between hypertrophic scars and keloids may be difficult. Normal skin contains distinct collagen bundles that run parallel to the epidermis. In hypertrophic scars, the collagen bundles are flatter, less demarcated, and are arranged in a wavy pattern although still oriented to the epithelial surface. In a keloid, collagen bundles are virtually nonexistent, and the fibers lie in loose, haphazardly oriented sheets.^[26]

Hypertrophic scars exhibit nodular structures containing fibroblastic cells and collagen. These nodules are not observed in normal dermis, other scars, or the majority of keloids evaluated.^[27] The nodules contain α -smooth muscle actin-staining myofibroblasts that may represent an important component in the pathogenesis of contraction.^[27]

3. Pathophysiology

3.1 Wound Healing

The normal sequence of wound healing is important in the understanding of the development and management of keloid and hypertrophic scars. Wound healing is arbitrarily divided into three stages: inflammatory, fibroblastic, and maturation. When skin injury is sustained, the complement cascade leads to the release of vasoactive mediators and chemotactic factors that stimulate the migration of inflammatory cells. Macrophages are involved in the release of cytokines that influence the wound environment and

play a pivotal role in the transition between the inflammatory and granulation phases of healing. In the fibroblastic phase, fibroblasts migrate into the area and produce a new structural framework through the deposition of type III and I collagen. In the normal maturation phase, there is a decrease of stimulatory and angiogenic factors with resultant regression of hyperemia associated with early wound repair. Simultaneous collagen synthesis and degradation during normal scar maturation results in decreased nodularity and flattening of the scar.^[28]

3.2 Pathophysiology

The exact pathophysiologic mechanisms leading to keloid or hypertrophic scar formation is unknown. Several studies have investigated the nature of keloids and hypertrophic scars at the cellular level. Fibroblast activity, extracellular matrix components, growth factors, cytokines, immunologic and other mechanisms have been investigated to delineate the molecular basis of the excessive fibrosis resulting in the formation of a keloid or hypertrophic scar.

Fibroblasts in keloids have different properties than those seen in normal skin and hypertrophic scars. Fibroblasts from keloids scars respond abnormally to stimulation, show a greater capacity to proliferate and produce high levels of collagen (predominantly type I), elastin, fibronectin, and proteoglycan.^[29-35] In contrast, hypertrophic scar fibroblasts respond normally to growth factors and demonstrate only a modest increase in collagen production.^[36] Some investigators have demonstrated an abnormal balance between proliferative and apoptotic cell death in fibroblasts derived from keloids and hypertrophic scars.^[37,38]

Growth factors known to modulate wound healing include transforming growth factor- β (TGF β), platelet-derived growth factor, and insulin-like growth factors (IGF). TGF β is released by platelets at the site of skin injury and is highly chemotactic for macrophages and monocytes to begin the production of extracellular matrix proteins. Several studies have demonstrated the association of TGF β with increased collagen or fibronectin synthesis by keloid fibroblasts.^[31,36,39-41] IGF-1 increases the expression of types I and III procollagen,^[42] and the IGF-1 receptor has been shown to be overexpressed in keloid fibroblasts.^[43] Aberrations in the levels of several cytokines, including interleukins 6, 13, and 15 may also have a role in keloid scar formation.^[44-46]

Hyaluronic acid is an extracellular matrix component that binds to fibroblast surface receptors. Hyaluronic acid is thought to induce localization of cytokines (particularly TGF β) to the fibroblast, which can stimulate collagen synthesis. However, research studies regarding hyaluronic acid are conflicting, with some authors^[47] demonstrating an increased production of hyaluronic

acid in keloidal fibroblasts as compared with normal fibroblasts and others^[48] finding lower concentrations of hyaluronic acid in the dermis of the keloids studied.

Although several studies support the hypothesis that immunologic mechanisms play an important role in keloid or hypertrophic scarring, the data are not conclusive. Some authors^[49,50] found a relationship with cell membrane proteins, such as HLA-DRB-16, B-14, and BW-16, whereas others have challenged these findings.^[51] Some investigators^[52] found elevated levels of IgA, IgG, and IgM, while others did not.^[53] The pathogenic factors involved in hypertrophic and keloid scars may be associated with an altered cellular immune response in the skin.^[54,55]

Other theories regarding the pathogenesis of keloid and hypertrophic scars include tissue hypoxia,^[56] an alteration in the fatty acid composition of the fibroblasts,^[57] high levels of nitric oxide during wound healing,^[58] and a possible immune response to sebum.^[59] Additional research is warranted to fully elucidate the validity of these possible etiologic factors.

4. Treatment of Keloid and Hypertrophic Scars

Prevention of keloid and hypertrophic scars is the best treatment strategy. Patients with a predisposition to develop excessive scar formation should avoid nonessential surgery, particularly in body locations at high risk for the development of keloids. Once a scar is present, there are many treatments from which to choose; however, there is no universally accepted treatment modality that results in complete and permanent hypertrophic scar or keloid amelioration.

4.1 Surgery

Surgical excision is usually followed by recurrence unless adjunct therapies are employed since the new surgical wound is subject to the same mechanical and biochemical forces of the original lesion. The recurrence rate has been reported to range from 45–100% when surgical excision is performed as monotherapy^[20,60,61] (figure 3). Furthermore, keloids that have recurred after excision are more likely to recur if excised again.^[7,62] Lee et al.^[63] recently demonstrated a 63% improvement in 24 keloids treated with core extirpation, a novel surgical technique for the treatment of keloids. Core extirpation consists of removal of the inner fibrous core leaving the shell of the keloid attached to the normal skin to function as a flap.

4.2 Radiation

Radiation therapy is infrequently used as monotherapy. When combined with surgical excision, the recurrence rate following radiation treatment has been reported between 10–20%.^[64,65] A

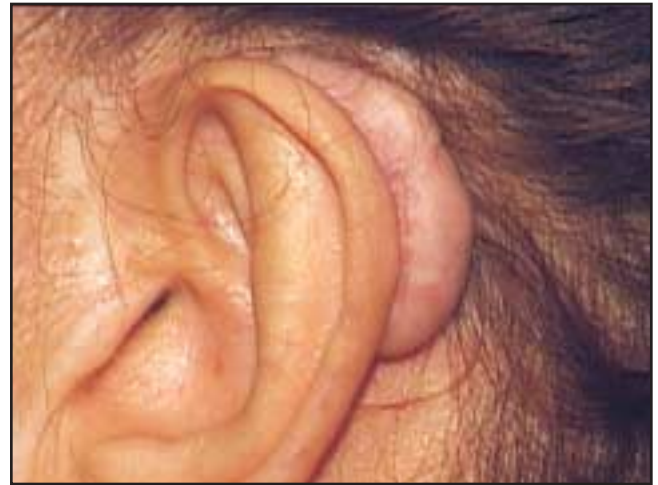

Fig. 3. Keloid recurrence after excision and continuous use of pressure earrings.

dose of at least 1500Gy, delivered in fractions within 10 days of surgery, is recommended by some investigators.^[66] Inhibition of fibroblast proliferation and angiogenesis during the exaggerated wound-healing process is the proposed mechanism of action.^[67] The use of a potentially carcinogenic treatment for the treatment of a benign process such as keloid scarring is controversial. Although a large study found no increased risk of malignancy following radiation therapy for keloids, case reports have outlined the development of carcinoma (two breast, one thyroid) in three patients.^[15,16,68] It is, therefore, prudent to exercise caution when considering radiation therapy as an adjunct to other modalities for the treatment of keloid or hypertrophic scars in young children and in radiosensitive areas such as the breast or thyroid.

4.3 Pressure Therapy

Compression therapy for keloids was initially reported in the 1960s.^[69] The mechanism by which continuous pressure decreases the size and thickness of hypertrophic scars and keloids is not completely understood. It is thought that continuous pressure exerts its effect by producing tissue ischemia, decreasing tissue metabolism and increasing collagenase activity.^[70-72] Other theories include pressure-induced release of metalloproteinase-9^[73] or prostaglandin E2^[74] that may effect scar softening by the induction of extracellular matrix remodeling.

Although pressure therapy has been shown in multiple studies to be effective, there are several disadvantages of treatment. It is necessary to wear the pressure dressing for at least 6 months for a minimum of 18 hours a day. Scars older than 6–12 months often respond poorly and it may be difficult to achieve the required amount of pressure (24–40mm Hg) in locations over a joint because of excessive skin movement.^[10,75] Moreover, many pa-

tients find the pressure dressing uncomfortable and cumbersome, limiting their compliance to the prescribed regimen.

4.4 Cryotherapy

Cryotherapy has been used as monotherapy and in combination with other techniques to treat keloid and hypertrophic scars. The mechanism by which cryotherapy exerts its therapeutic effect depends upon freezing-induced ischemic damage to the microcirculation. Freezing induces vascular damage and circulatory stasis leading to anoxia with eventual necrosis.^[15,28] Therapy typically involves treating the entire scar with two or three freeze-thaw cycles of 30 seconds each. Several authors^[76-78] have reported good responses in the majority of patients treated; however, facial keloids and scars older than 12 months show poor response to treatment. Cryotherapy may be more effective when combined with other procedures such as intralesional corticosteroids.^[79] Hypopigmentation resulting from the cold sensitivity of melanocytes is often permanent and renders cryotherapy less desirable in patients with darker skin phototypes.

4.5 Silicone Gel Sheeting and Other Dressings

Multiple studies have demonstrated significant scar softening and decreased pruritus following application of topical silicone gel sheeting or cushions for at least 12 hours daily for 2–4 months.^[80-86] Silicone sheeting has also been used to prevent hypertrophic scarring.^[87] The mechanism of action is not completely understood, but it has been suggested that hydration, not pressure or silicone, may lead to fibroblast modification.^[88] Although many of the studies previously performed using silicone dressings lacked adequate controls,^[15] the relatively benign nature of this treatment makes it a popular treatment option.

4.6 Intralesional Corticosteroids

Intralesional corticosteroids have become a cornerstone of both treatment and prophylaxis of hypertrophic scars and keloids. Studies have documented softening, flattening, and improvement of symptoms as endpoints of treatment.^[89-91] When used in combination with surgical excision, the recurrence rate falls below 50%.^[92] One study that evaluated patients 5 years following intralesional corticosteroid treatment showed an initial response of 90%; however, up to 50% of patients had keloid recurrence within 5 years.^[93] Based on an evidence-based approach to scar management, Mustoe and colleagues^[94] highlighted a primary role for silicone gel sheeting and intralesional corticosteroids in the treatment of a wide variety of abnormal scars. The most commonly used drug for intralesional corticosteroid injection is triamcinolone acetonide, which can be diluted with lidocaine to decrease the

discomfort of the injection. Some investigators have used intralesional hyaluronidase or light cryotherapy immediately prior to injection to facilitate dispersal of the corticosteroid.^[10,13] The mechanism of corticosteroid action is related to suppression of collagen synthesis by decreased gene expression within the keloid or hypertrophic scar. Adverse effects of treatment include pain with injection, atrophy, telangiectasia, and, most troubling in patients with type V and VI phototypes, hypopigmentation that may last longer than a year following treatment.

4.7 Interferon

Based on the premise that interferon can decrease the production of types I and III collagen from fibroblasts, several groups have demonstrated improvement in keloid or hypertrophic scars following intralesional interferon injection.^[95-97] Although improvements of up to 50% have been reported, the efficacy of interferon for the treatment of keloids has been questioned.^[98,99]

4.8 Fluorouracil

Two studies have demonstrated improvement following the intralesional use of fluorouracil. Fitzpatrick^[100] reported improvement in the majority of 1000 patients treated with this technique; however, in several cases, the fluorouracil was used in conjunction with other modalities such as pulsed dye laser irradiation or intralesional corticosteroids. Another group^[101] reported short-term improvement in five patients whose surgical wounds were treated with fluorouracil as compared with saline. Additional prospective, well-controlled clinical studies are warranted to determine the efficacy of fluorouracil for the treatment of patients with hypertrophic scars and keloids.

4.9 Laser

Advances in laser technology and refinements in technique have made laser therapy one of the most advantageous modalities for the treatment of hypertrophic scars and keloids. In the 1980s, there was great controversy among laser surgeons regarding the benefits of keloid vaporization with various lasers (carbon dioxide, argon, and neodymium: yttrium-aluminum-garnet [Nd:YAG]). Ultimately, none of the preliminary studies with the aforementioned laser systems demonstrated an advantage over scalpel excision, with unacceptably high rates of scar recurrence and other adverse effects including pain, atrophy, and dyspigmentation.^[28,102-108] During the past decade; however, multiple studies using the flashlamp-pumped pulsed-dye laser (PDL) have demonstrated striking improvements in scar erythema, texture, height, and pliability.^[109-118] In 1993, Alster and colleagues^[110] were the first to demonstrate improvement in argon laser-induced hyper-

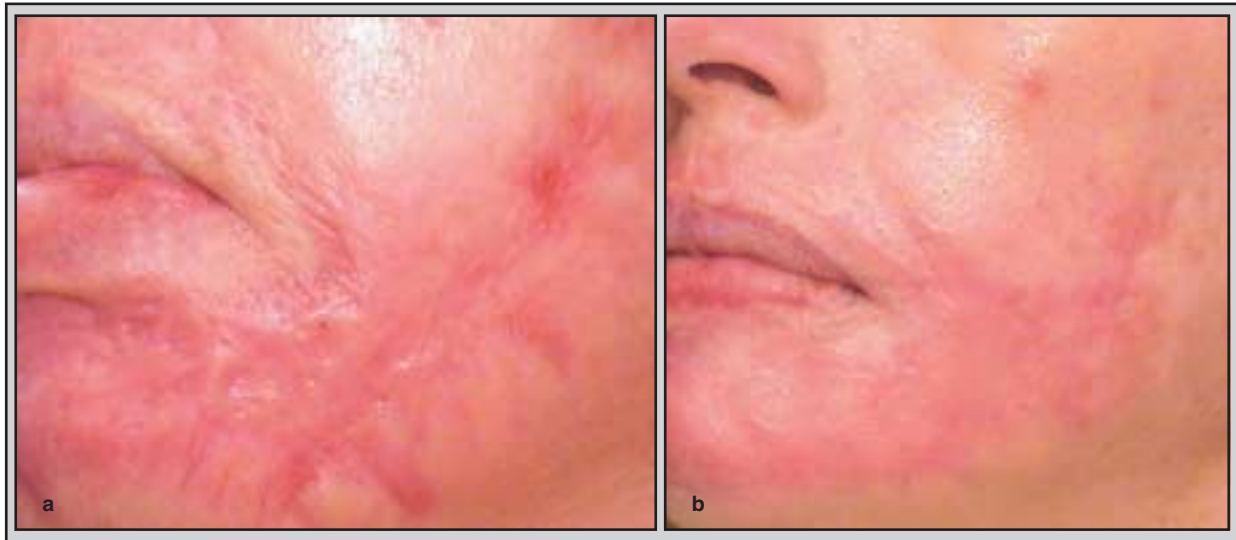


Fig. 4. (a) Hypertrophic burn scars after compression therapy and intralesional corticosteroids; and (b) improvement of scars seen 2 months after one 585nm pulsed dye laser (PDL) treatment.

trophic scars over a 10-month period following five PDL treatments. Using optical profilometry to measure skin surface texture, the authors showed a return of normal skin markings after laser treatment in all 10 patients. The study represented the first use of an objective parameter to assess the degree of scar improvement. In 1995, Alster and Williams^[114] performed the first controlled study of the response of hypertrophic scars and keloids to the PDL on median sternotomy scar halves. Significant improvement in scar texture, erythema, height, pliability, and symptomatology were seen in all 16 study patients with minimal adverse effects or treatment discomfort. Others have demonstrated that keloids and very thick or proliferative hypertrophic scars may require additional laser treatment or simultaneous use of intralesional corticosteroid or fluorouracil injections to enhance clinical results.^[119] Given its utility and low adverse effect profile, the PDL has become a popular technique for the treatment of keloid and hypertrophic scars (figure 4).

Initially, the PDL was used to target the vascular component of scars to reduce or eliminate persistent erythema, with the flattening and increased pliability of the treated scars being an incidental finding. Currently, there is no consensus on the mechanism by which the PDL achieves these additional clinical effects. It has been hypothesized that laser-induced tissue hypoxia leads to decreased cellular function, laser-induced heating leads to disulfide bond disruption with subsequent remodeling of the fibers, or collagenolysis occurs following cytokine stimulation.^[114,116,117]

4.10 Other Treatments

Multitudes of other modalities have been used in the treatment of hypertrophic scars and keloids; however, the studies evaluating the efficacy of these treatments are often limited by poor study design, a paucity of subjects, and short-term follow-up. Bleomycin,^[120] tamoxifen,^[121,122] tretinoin,^[123] tacrolimus,^[124] pentoxifylline, colchicine, calcium antagonists, tranilast, zinc, and vitamin E^[5,10] have all been tried with varying success.

One of the most promising topical agents for the treatment of keloids is the local immunomodulator, imiquimod. By inducing local interferons at the site of application, downregulation of collagen synthesis may be achieved. In a pilot study, Berman et al.^[125] recently evaluated 13 keloids after surgical excision followed by imiquimod application initiated the night of surgery and continued for 8 weeks. Of the 11 keloids evaluated at the 24-week follow-up visit, there were no recurrences observed.

5. Conclusion

The management of hypertrophic scars and keloids remains a challenge. Multiple treatments have been advocated in the past with varying degrees of success. Hypertrophic scars and keloids have been shown to respond to pressure therapy, cryotherapy, intralesional corticosteroids, radiation treatment, topical silicone or other dressings, and laser treatment. Simple excision or vaporization of these proliferative scars often leads to recurrence. In the future, biologic agents directed toward the aberrant proliferative collagen metabolism of scars may add to the current armamentarium of treatment modalities.

Acknowledgements

No sources of funding were used to assist in the preparation of this manuscript. The authors have no conflicts of interest that are directly relevant to the content of this manuscript.

References

- Breasted HG. The Edwin Smith surgical papyrus: hieroglyphic translation and commentary. Chicago: University of Chicago Press, 1930
- Alibert JLM. Quelques recherches sur la cheloïde. Mem Soc Medicale d'Emulation 1917; 8: 744-52
- Urioste SS, Arndt KA, Dover JS. Keloidal scars and hypertrophic scars: review and treatment strategies. Semin Cutan Med Surg 1999; 18: 159-71
- Muir IFK. On the nature of keloidal scars and hypertrophic scars. Br J Plast Surg 1990; 43: 61-9
- Niessen FB, Spauwen PH, Schalkwijk J, et al. On the nature of hypertrophic scars and keloidal scars: a review. Plast Reconstr Surg 1999; 105: 1435-58
- Datubo-Brown DD. Keloids: a review of the literature. Br J Plast Surg 1990; 43: 276-80
- Cosman B, Crikelair GF, Ju MC, et al. The surgical treatment of keloidal scars. Plast Reconstr Surg 1961; 27: 335-58
- Larrabee Jr WF, East CA, Jaffe HS, et al. Intralesional interferon gamma treatment for keloidal scars and hypertrophic scars. Arch Otolaryngol Head Neck Surg 1990; 116: 1159-62
- Pollack SV, Goslen JB. The surgical treatment of keloidal scars. J Dermatol Surg Oncol 1982; 8: 1045-9
- English RS, Shenefelt PD. Keloids and hypertrophic scars. Dermatol Surg 1999; 25: 631-8
- Murray J. Scars and keloids. Dermatol Clin 1993; 11: 697-708
- Stegman SL, Tromovitch TA, Glogan RG. Treatment of keloids. In: Stegman SJ, editor. Cosmetic dermatologic surgery. 2nd ed. Chicago: Year Book Medical, 1990: 201-6
- Stucker FJ, Shaw GY. An approach to management of keloids. Arch Otolaryngol Head Neck Surg 1992; 118: 63-7
- Ketchum LD, Cohen IK, Masters FW. Hypertrophic scars and keloids. Plast Reconstr Surg 1974; 53: 140-53
- Shaffer JJ, Taylor SC, Cook-Bolden F. Keloidal scars: a review with a critical look at therapeutic options. J Am Acad Dermatol 2002; 46: S63-97
- Matas R. The surgical peculiarities of the Negro. Tr Am Surg A 1896; 14: 483-5
- Abrams BJ, Benedetto AV, Humeniuk HM. Exuberant keloidal formation. J Am Osteopath Assoc 1993; 93: 863-5
- Rockwell WB, Cohen IK, Ehrlich HP. Keloids and hypertrophic scars: a comprehensive review. Plast Reconstr Surg 1989; 84: 827-37
- Alhady SM, Sivanantharajah K. Keloids in various races: a review of 175 cases. Plast Reconstr Surg 1969; 44: 564-6
- Mathangi-Ramakrishnan K, Pothan-Thomas K, Cheyyur R. Study of 1000 patients with keloidal scars in south India. Plast Reconstr Surg 1974; 53: 276-80
- Davies DM. Scars, hypertrophic scars and keloids. Plast Reconstr Surg 1985; 290: 1056-8
- Marneros AG, Norris JE, Olsen BR, et al. Clinical genetics of familial keloids. Arch Dermatol 2001; 137: 1429-34
- Crockett DJ. Regional keloid susceptibility. Br J Plast Surg 1964; 17: 245-53
- Fong EP, Chye LT, Tan WL. Keloids: time to dispel the myths? Plast Reconstr Surg 1999; 104: 1199-201
- Sherris DA, Larrabee WF, Murakami CS. Management of scar contractures, hypertrophic scars and keloidal scars. Otolaryngol Clin North Am 1995; 28: 1057-68
- Kazeem AA. The immunological aspects of keloid tumor formation. J Surg Oncol 1988; 38: 16-8
- Ehrlich HP, Desmouliere A, Diegelmann RF, et al. Morphological and immunohistochemical differences between keloid and hypertrophic scars. Am J Pathol 1994; 145: 105-13
- Alster TS, West TB. Treatment of scars: a review. Ann Plast Surg 1997; 39: 418-32
- Abergel RP, Pizzurro D, Meeker CA, et al. Biochemical composition of the connective tissue in keloids and analysis of collagen metabolism in keloid fibroblast cultures. J Invest Dermatol 1985; 84: 384-90
- Russell SR, Trupin JS, Kennedy RZ, et al. Glucocorticoid regulation of elastin synthesis in human fibroblasts: down regulation in fibroblasts from normal dermis but not from keloids. J Invest Dermatol 1995; 105: 241-5
- Babu M, Diegelmann R, Oliver N. Fibronectin is overproduced by keloid fibroblasts during abnormal wound healing. Mol Cell Biol 1989; 9: 1642-50
- Kischer CW, Hendrix MJ. Fibronectin in hypertrophic scars and keloids. Cell Tissue Res 1983; 231: 29-37
- McCoy BJ, Cohen IK. Effects of various sera on growth kinetics and collagen synthesis by keloid and normal dermal fibroblasts. Plast Reconstr Surg 1981; 67: 505-10
- Bettinger DA, Yager DR, Diegelmann RF, et al. The effects of TGF-beta on keloid fibroblast proliferation and collagen synthesis. Plast Reconstr Surg 1996; 98: 827-33
- Calderon M, Lawrence WT, Banes AJ. Increased proliferation of keloid fibroblasts in vitro. J Surg Res 1996; 61: 343-7
- Younai S, Nichter LS, Wellisz T, et al. Modulation of collagen synthesis by transforming growth factor beta in keloid and hypertrophic scar fibroblasts. Ann Plast Surg 1994; 33: 148-51
- Luo S, Benathan M, Raffoul W, et al. Abnormal balance between proliferation and apoptotic cell death in fibroblasts derived from keloid lesions. Plast Reconstr Surg 2001; 107: 87-96
- Akasaka Y, Fujita K, Ishikawa Y, et al. Detection of apoptosis in keloids and a comparative study on apoptosis between keloids, hypertrophic scars, normal healed flat scars, and dermatofibroma. Wound Repair Regen 2001; 9: 501-6
- Peltonen J, Hsiao LL, Jaakola S, et al. Activation of collagen gene expression in keloids: co-localization of type I and VI collagen and transforming growth factor beta 1 mRNA. J Invest Dermatol 1992; 99: 650-5
- Smith P, Mosiello G, Deluca L, et al. TGF-beta2 activates proliferative scar fibroblasts. J Surg Res 1999; 82: 319-23
- Wang X, Smith P, Pu LLQ, et al. Exogenous transforming growth factor beta2 modulates collagen I and collagen III synthesis in proliferative scar xenografts in nude rats. J Surg Res 1999; 87: 194-200
- Ghahary A, Shen YJ, Nedelec B, et al. Enhanced expression of mRNA for insulin-like growth factor-1 in post burn hypertrophic scar tissue and its fibrogenic role by dermal fibroblasts. Mol Cell Biochem 1995; 148: 25-32
- Yoshimoto H, Hiroshi I, Ohtsuru A, et al. Overexpression of insulin-like growth factor-1 (IGF-1) receptor and the invasiveness of cultured keloid fibroblasts. Am J Pathol 1999; 154: 883-9
- Xue H, McCauley RL, Zhang W. Elevated interleukin-6 expression in keloid fibroblasts. J Surg Res 2000; 89: 74-7
- Oriente A, Fedarko NS, Pacocha SE, et al. Interleukin-13 modulates collagen homeostasis in human skin and keloid fibroblasts. J Pharmacol Exp Ther 2000; 292: 988-94
- Castagnoli C, Trombotto C, Ariotti S, et al. Expression and role of IL-15 in post-burn hypertrophic scars. J Invest Dermatol 1999; 113: 238-45
- Alaish SM, Yager DR, Diegelmann RF, et al. Hyaluronic acid metabolism in keloid fibroblasts. J Pediatr Surg 1995; 30: 949-52
- Bertheim U, Hellstrom S. The distribution of hyaluronan in human skin and mature, hypertrophic and keloid scars. Br J Plast Surg 1994; 47: 483-9
- Castagnoli C, Stella M, Magliacani G, et al. Anomalous expression of HLA class II molecules on keratinocytes and fibroblasts in hypertrophic scars consequent to thermal injury. Clin Exp Immunol 1990; 82: 350-4
- Castagnoli C, Perruccio D, Stella M, et al. The HLA-DR beta 16 allelogroup constitutes a risk factor for hypertrophic scarring. Hum Immunol 1990; 29: 229-32
- Cohen IK, McCoy BJ, Mohanakumar T, et al. Immunoglobulin, complement and histocompatibility antigen studies in keloid patients. Plast Reconstr Surg 1979; 63: 689-95
- Kischer CW, Shetlar MR, Shetlar CL, et al. Immunoglobulins in hypertrophic scars and keloids. Plast Reconstr Surg 1983; 71: 821-5
- Bloch EF, Hall MG, Denson MJ, et al. General immune reactivity in keloid patients. Plast Reconstr Surg 1984; 73: 448-51
- Boyce DE, Ciampolini J, Ruge F, et al. Inflammatory cell populations in keloid scars. Br J Plast Surg 2001; 54: 511-6

55. Bernabei P, Rigamonti L, Ariotti S, et al. Functional analysis of T lymphocytes infiltrating the dermis and epidermis of post-burn hypertrophic scar tissues. *Burns* 1999; 25: 43-8
56. Kischer CW, Thies AC, Chvapil M. Perivascular myofibroblasts and microvascular occlusion in hypertrophic scars and keloids. *Hum Pathol* 1982; 13: 819-24
57. Louw L, Engelbrecht AM, Cloete F, et al. Impairment in the fatty acid composition of keloidal scars. In: Honn KV, Nigam S, Marnett LJ, editors. *Eicosanoids and other bioactive lipids in cancer inflammation and radiation injury 2*. Chapter 116. New York: Plenum Press, 1997: 905-10
58. Cobbold CA, Sherratt JA. Mathematical modeling of nitric oxide activity in wound healing can explain keloid and hypertrophic scarring. *J Theor Biol* 2000; 204: 257-88
59. Yagi K, Dafalla AA, Osman AA. Does an immune reaction to sebum in wounds cause keloid scars?: beneficial effect of desensitization. *Br J Plast Surg* 1979; 32: 223-7
60. Cosman B, Wolff M. Correlation of keloid recurrence with completeness of local excision: a negative report. *Plast Reconstr Surg* 1972; 50: 163-6
61. Lawrence WT. In search of the optimal treatment of keloids: report of a series and a review of the literature. *Ann Plast Surg* 1991; 27: 164-78
62. Kovalic JJ, Perez CA. Radiation therapy following keloidectomy: a 20-year experience. *Int J Radiat Oncol Biol Phys* 1989; 17: 77-80
63. Lee Y, Minn KW, Baek RM, et al. A new surgical treatment of keloid: keloid core excision. *Ann Plast Surg* 2001; 46: 135-40
64. Sclafani AP, Gordon L, Chadha M, et al. Prevention of earlobe keloid recurrence with postoperative corticosteroid injections versus radiation therapy. *Dermatol Surg* 1996; 22: 569-74
65. Ragoowansi R, Cornes PGS, Glees JP, et al. Ear-lobe keloids: treatment by a protocol of surgical excision and immediate postoperative adjuvant radiotherapy. *Br J Plast Surg* 2001; 54: 504-8
66. Doombos JF, Stoffel TJ, Hass AC, et al. The role of kilovoltage irradiation in the treatment of keloids. *Int J Radiat Oncol Biol Phys* 1990; 18: 833-9
67. Ship AG, Weiss PR, Mincer FR, et al. Sternal keloids: successful treatment employing surgery and adjuvant radiation. *Ann Plast Surg* 1993; 31: 481-7
68. Botwood N, Lewanski C, Lowdell C. The risks of treating keloids with radiotherapy. *Br J Radiol* 1999; 72: 1222-4
69. Cronin TD. The use of a molded splint to prevent contracture after split skin grafting on the neck [letter]. *Plast Reconstr Surg* 1961; 27: 7
70. Bauer PS, Larson DL, Stacey TR, et al. Ultrastructural analysis of pressure treated human hypertrophic scars. *J Trauma* 1976; 16: 958-67
71. Brent B. The role of pressure therapy in management of earlobe keloids: preliminary report of a controlled study. *Ann Plast Surg* 1978; 1: 579-81
72. Russell R, Horlock N, Gault D. Zimmer splintage: a simple effective treatment for keloids following ear-piercing. *Br J Plast Surg* 2001; 54: 509-10
73. Reno F, Grazianetti P, Stella M, et al. Release and activation of matrix metalloproteinase-9 during in vitro mechanical compression in hypertrophic scars. *Arch Dermatol* 2002; 138: 475-8
74. Reno F, Grazianetti P, Cannas M. Effects of mechanical compression on hypertrophic scars: prostaglandin E2 release. *Burns* 2001; 27: 205-14
75. Ahn ST, Mustoe TA, Monafó WW. Topical silicone gel: a new treatment for hypertrophic scars. *Surgery* 1989; 106: 781-7
76. Rusciani L, Rossi G, Bono R. Use of cryotherapy in the treatment of keloids. *J Dermatol Surg Oncol* 1993; 19: 529-34
77. Zouboulis CC, Blume U, Buttner P, et al. Outcomes of cryosurgery in keloids and hypertrophic scars. *Arch Dermatol* 1993; 129: 1146-51
78. Layton AM, Yip J, Cunliffe WJ. A comparison of intralesional triamcinolone and cryosurgery in the treatment of acne keloids. *Br J Dermatol* 1994; 130: 498-501
79. Lahiri A, Tsiliboti D, Gaze NR. Experience with difficult keloids. *Br J Plast Surg* 2001; 54: 633-5
80. Perkins K, Davey RB, Wallis KA. Silicone gel: a new treatment for burn scars and contractures. *Burns* 1983; 9: 201-4
81. Mercer DM. Silicone gel in the treatment of keloids scars. *Br J Plast Surg* 1989; 42: 83-7
82. Ahn ST, Monafó WW, Mustoe TA. Topical silicone gel for prevention and treatment of hypertrophic scars. *Arch Surg* 1991; 126: 499-504
83. Berman B, Bielek HC. Adjuvant therapies to surgical management of keloids. *Dermatol Surg* 1996; 22: 126-30
84. Fulton Jr JE. Silicone gel sheeting for the prevention and management of evolving hypertrophic and keloids scars. *Dermatol Surg* 1995; 21: 947-51
85. De Oliveira GV, Nunes TA, Magna LA. Silicone versus nonsilicone gel dressings: a controlled trial. *Dermatol Surg* 2001; 27: 721-6
86. Berman B, Flores F. Comparison of a silicone gel-filled cushion and silicon gel sheeting for the treatment of hypertrophic of keloids scars. *Dermatol Surg* 1999; 25: 484-6
87. Gold MH, Foster TD, Adair MA, et al. Prevention of hypertrophic scars and keloids by the prophylactic use of topical silicone gel sheets following a surgical procedure in an office setting. *Dermatol Surg* 2001; 27: 641-4
88. Beranak JT. Silicone gel sheeting for the management of hypertrophic and keloids scars: the mechanism of its action. *Dermatol Surg* 1997; 23: 401-5
89. Darzi MA, Chowdri NA, Kaul SK, et al. Evaluation of various methods of treating keloids and hypertrophic scars: a 10-year follow-up study. *Br J Plast Surg* 1992; 45: 374-9
90. Griffith BH. The treatment of keloids with triamcinolone acetonide. *Plast Reconstr Surg* 1966; 38: 202-8
91. Griffith BH, Monroe CW, McKinney P. A follow-up study on the treatment of keloids with triamcinolone acetonide. *Plast Reconstr Surg* 1970; 46: 145-50
92. Chowdri NA, Mattoo MMA, Darzi MA. Keloids and hypertrophic scars: results with intraoperative and serial postoperative corticosteroid injection therapy. *Aust N Z J Surg* 1999; 69: 655-9
93. Kill J. Keloids treated with topical injections of triamcinolone acetonide (Kenalog). *Scand J Plast Reconstr Surg* 1977; 11: 169-72
94. Mustoe TA, Cooter RD, Gold MH, et al. International clinical recommendations on scar management. *Plast Reconstr Surg* 2002; 110: 560-71
95. Berman B, Flores F. Recurrence rates of excised keloids treated with postoperative triamcinolone acetonide injections or interferon alfa-2b injections. *J Am Acad Dermatol* 1997; 37: 755-7
96. Conejo-Mir JS, Corbi R. Carbon dioxide laser ablation associated with interferon alfa-2b injection reduces the recurrence of keloids. *J Am Acad Dermatol* 1998; 39: 1039-40
97. Granstein RD, Rook A, Flotte TJ, et al. A controlled trial of intralesional recombinant interferon-gamma in the treatment of keloidal scarring: Clinical and histologic findings. *Arch Dermatol* 1990; 126: 1295-302
98. Wong TW, Chiu HC, Yip KM. Intralesional interferon alfa-2b has no effect in the treatment of keloids. *Br J Dermatol* 1994; 130: 683-5
99. Al-Khawajah MM. Failure of interferon alfa-2b in the treatment of mature keloids. *Int J Dermatol* 1996; 35: 515-7
100. Fitzpatrick RE. Treatment of inflamed hypertrophic scars using intralesional 5-FU. *Dermatol Surg* 1999; 25: 224-32
101. Uppal RS, Khan U, Kakar S, et al. The effects of a single dose of 5-fluorouracil on keloids scars: a clinical trial of timed wound irrigation after extralesional excision. *Plast Reconstr Surg* 2001; 108: 1218-24
102. Abergel RP, Dwyer RM, Meeker CA, et al. Laser treatment of keloids: a clinical trial and an in vitro study with Nd: YAG laser. *Lasers Surg Med* 1984; 4: 291-5
103. Apfelberg DB, Maser MR, White DN, et al. Failure of carbon dioxide laser excision of keloids. *Lasers Surg Med* 1989; 9: 382-8
104. Apfelberg DB, Maser MR, Lash H, et al. Preliminary results of argon and carbon dioxide laser treatment of keloids scars. *Lasers Surg Med* 1984; 4: 283-90
105. Henderson DL, Cromwell TA, Mes LG. Argon and carbon dioxide laser treatment of hypertrophic and keloids scars. *Lasers Surg Med* 1984; 3: 271-7
106. Hulsbergen-Henning JP, Roskam Y, van Gemert MJ. Treatment of keloids and hypertrophic scars with an argon laser. *Lasers Surg Med* 1986; 6: 72-7
107. Sherman R, Rosenfeld H. Experience with the Nd: YAG laser in the treatment of keloids scars. *Ann Plast Surg* 1988; 21: 231-5
108. Stern JC, Lucente FE. Carbon dioxide laser excision of earlobe keloids: a prospective study and critical analysis of existing data. *Arch Otolaryngol Head Neck Surg* 1989; 115: 1107-11
109. Alster TS. Improvement of erythematous and hypertrophic scars by the 585nm pulsed dye laser. *Ann Plast Surg* 1994; 32: 186-90
110. Alster TS, Kurban AK, Grove GL, et al. Alteration of argon laser-induced scars by the pulsed dye laser. *Lasers Surg Med* 1993; 13: 368-73
111. Alster TS, Lewis AB, Rosenbach A. Laser scar revision: comparison of CO2 laser vaporization with and without simultaneous pulsed dye laser. *Dermatol Surg* 1998; 24: 1299-302

112. Alster TS, McMeekin TO. Improvement of facial acne scars by the 585nm flashlamp-pumped pulsed dye laser. *J Am Acad Dermatol* 1996; 35: 79-81
113. Alster TS, Nanni CA. Pulsed dye laser treatment of hypertrophic burn scars. *Plast Reconstr Surg* 1998; 102: 2190-5
114. Alster TS, Williams CM. Treatment of keloids sternotomy scars with the 585nm flashlamp-pumped pulsed dye laser. *Lancet* 1995; 345: 1198-200
115. Manuskiatti W, Fitzpatrick RE, Goldman MP. Energy density and numbers of treatment affect response of keloidal and hypertrophic sternotomy scars to the 585-nm flashlamp-pumped pulsed-dye laser. *J Am Acad Dermatol* 2001; 45: 557-65
116. Dierickx C, Goldman MP, Fitzpatrick RE. Laser treatment of erythematous/hypertrophic and pigmented scars in 26 patients. *Plast Reconstr Surg* 1995; 95: 84-90
117. Lupton JR, Alster TS. Laser scar revision. *Dermatol Clin* 2002; 20: 55-65
118. Alster TS. Laser scar revision: comparison of pulsed dye laser with and without intralesional corticosteroids. *Dermatol Surg* 2002; 29: 25-9
119. Manuskiatti W, Fitzpatrick RE. Treatment response of keloidal and hypertrophic sternotomy scars: comparison among intralesional corticosteroid, 5-fluorouracil, and 585-nm flashlamp-pumped pulsed-dye laser treatments. *Arch Dermatol* 2002; 138: 1149-55
120. Espana A, Solano T, Quintanilla E. Bleomycin in the treatment of keloids and hypertrophic scars by multiple needle punctures. *Dermatol Surg* 2001; 27: 23-7
121. Mikulec AA, Hanasono MM, Lum J, et al. Effect of tamoxifen on transforming growth factor beta1 production by keloids and fetal fibroblasts. *Arch Facial Plast Surg* 2001; 3: 111-4
122. Chau D, Mancoll JS, Lee S, et al. Tamoxifen down regulates TGF-beta production in keloid fibroblasts. *Ann Plast Surg* 1998; 40: 490-3
123. Panabiere-Castaings MH. Retinoic acid in the treatment of keloids. *J Dermatol Surg Oncol* 1988; 14: 1275-6
124. Kim A, DeCarlo J, Cohen C, et al. Are keloids really "gli-oids"? high-level expression of gli-1 oncogene in keloids. *J Am Acad Dermatol* 2001; 45: 707-11
125. Berman B, Kaufman J. Pilot study of the effect of postoperative imiquimod 5% cream on the recurrence rate of excised keloids. *J Am Acad Dermatol* 2002; 47: S209-11

Correspondence and offprints: Dr *Tina S. Alster*, The Washington Institute of Dermatologic Laser Surgery, 2311 M Street NW, Suite 200, Washington, DC 20037, USA.

E-mail: talster@skinlaser.com