

ORIGINAL ARTICLE

Cellulite treatment using a novel combination radiofrequency, infrared light, and mechanical tissue manipulation device

TINA S. ALSTER & ELIZABETH L. TANZI

Washington Institute of Dermatologic Laser Surgery, Washington, DC, USA

Abstract

Background. Most post-pubertal women exhibit cellulite, particularly in the thigh and buttock regions. The prevalence of cellulite has led to many attempts at treatment, including a variety of topical solutions, massage-based therapies, and surgical techniques—most with suboptimal clinical effects. The purpose of this controlled study was to evaluate a novel combination device involving radiofrequency, infrared light, and mechanical tissue manipulation for the treatment of cellulite.

Methods. Twenty adult women (ages 25–57 years) of various skin phototypes (I–V), and with moderate bilateral thigh and buttock cellulite, received eight biweekly treatments to a randomly selected side (the contralateral side serving as a non-treated control). A combined bipolar radiofrequency, infrared light, and mechanical suction-based massage device was applied at 20 watts RF, 20 watts IR (700–1500 nm) light, and 200 millibar vacuum (750 mmHg negative pressure). Patients were evaluated using standardized digital photography and circumferential leg measurements at baseline, prior to each treatment session, and at one, three, and six months after the final treatment. Clinical improvement scores of comparable photographs using a quartile grading scale (0 = <25%, 1 = 25%–50%, 2 = 51%–75%, 3 = >75% improvement) were made independently by two masked medical assessors after the series of treatments. Final post-treatment body weight and patients' subjective evaluations were recorded.

Results. Ninety per cent (18/20) of patients noticed overall clinical improvement, and 17 of these 18 patients reported that they would pursue treatment of the contralateral thigh. Side effects were limited to transient erythema in most patients, and bruising was observed in 2/20 patients after the first couple of treatment sessions, but not as the treatment series progressed. Clinical improvement scores averaged 1.82 (corresponding to ~50% improvement) after the series of treatments. Circumferential thigh measurements were reduced by 0.8 cm on the treatment side.

Conclusions. Cellulite can be significantly and safely reduced with the use of a noninvasive device that combines bipolar RF, infrared light, and mechanical massage. The effects of treatment appear to be prolonged, but maintenance treatments may be necessary to further enhance the clinical results achieved.

1 Key words:

Introduction

Cellulite is a common and perturbing physiologic condition experienced by most post-pubertal women. It is clinically manifest by irregular skin contours or dimpling of the skin, most commonly in the thigh and buttock regions. It is caused by excess adipose tissue retention within fibrous septae. The skin irregularity is proportional to the subcutaneous fat projected into the upper dermis. The fibrous septae sequester fat in discrete packets and the vertically oriented bands are anchored to the deep fascia, causing the skin surface to pucker.

The etiology of cellulite is unknown, but is determined by the amount of body fat and the nature of the supporting fibrous septae. Women

have more body fat (27%) compared to men (15%) of proportional body fitness (see (1), p. 1059). Estrogen increases metabolic rate at one-third the level of testosterone, causing a significant generalized increase in fat deposition in the subcutaneous tissue of women (see (1), p. 1024). Much gender-specific fat deposition is based upon hormonal receptor site density and sensitivity in different body regions, with insulin exerting an inhibitory effect on lipolysis and facilitating increased glucose entry into adipocytes (2),(3). Histologic analysis of fibrous septae in cellulite has shown inflammation (4), which accounts for localized edema with subsequent increased projection of adipose tissue. A functional defect in lymphatic drainage has also been proposed to lead to fluid accumulation within fibrous septae,

Correspondence: T. S. Alster, Washington Institute of Dermatologic Laser Surgery, Washington, DC, USA

(Received 27 April 2005; accepted 1 May 2005)

ISSN 1476-4172 print/ISSN 1476-4180 online © 2005 Taylor & Francis Group Ltd
DOI: 10.1080/14764170500190242

as has slowed circulation which increases lipogenesis (5). Changes in capillary dynamics cause increased protein and fluid extravasation which further slows circulation and increases acidosis, ultimately leading to sclerosis, interstitial fibrosis, and decreased venous return and lymphatic flow, causing adipocyte deformity and the characteristic skin contour irregularities of cellulite (6).

Good diet and physical conditioning do not uniformly prevent the development of cellulite. The prevalence of this cosmetically unappealing condition has led to many attempts at treatment. A variety of topical solutions, massage-based therapies, and surgical techniques, including liposuction and subcision, have been advocated to promote micro-circulation and therefore reduce cellulite — most with suboptimal clinical effects (7). More recently, nonablative lasers and radiofrequency systems have been shown to improve skin surface texture due to selective dermal heating which effects neocollagenesis (8),(9).

The purpose of this controlled study was to evaluate a novel combination device involving radio-frequency, infrared light, and mechanical manipulation for the treatment of cellulite.

Materials and methods

Twenty healthy adult women (ages 25–57 years, mean 48.1 years) of various skin phototypes (I–V) were cleared for study entry. Patient inclusion criteria were the presence of moderate bilateral thigh and buttock cellulite with photographable skin contour irregularities, adherence to a regular diet and exercise program, and lack of weight change fluctuations exceeding 10 pounds in the preceding month. Patients were excluded from study entry if pregnant or lactating, receiving concomitant cellulite treatments, following fad diets, had a history of diabetes or other systemic hormonal irregularities, had concomitant inflammatory or infectious skin conditions in the treatment areas, or if a history of deep venous thrombosis, arterial disease of the legs, or congestive heart failure was present.

Baseline body weight, clinical photographic assessments, and circumferential thigh measurements were obtained prior to treatment. All treatments were delivered to a randomly selected upper anteromedial and postelateral thigh and buttock (using the contralateral side as a non-treated comparative control). Eight 30-minute treatment sessions using a combination radiofrequency (RF), infrared (IR) light, and mechanical suction-based massage device (VelaSmooth, Syneron Medical, Ontario, Canada) were delivered to the randomly selected thigh and buttock twice a week over a one-month period. All treatments were performed by a single operator at RF (1 MHz) power of 20 watts, IR light (700–1500 nm) power of 20 watts, and vacuum

level of 200 millibar (750 mmHg negative pressure). Four to six (average, five) passes of the device were applied to each treatment area.

Side effects of treatment were recorded at every session. Standardized digital photographs using consistent patient positioning, camera angling, lighting, and backdrop conditions were obtained, as well as circumferential thigh measurements prior to each treatment and at one, three and six months post-treatment. Clinical improvement scores of comparable photographs using a quartile grading scale (0 = <25%, 1 = 25%–50%, 2 = 51%–75%, 3 = >75% improvement) were made independently by two masked medical assessors after the series of treatments. All photographs were shown in random order: first, to determine whether improvement could be ascertained, and, secondly, for clinical grading. Final post-treatment body weight and patients' subjective evaluations of treatment were recorded.

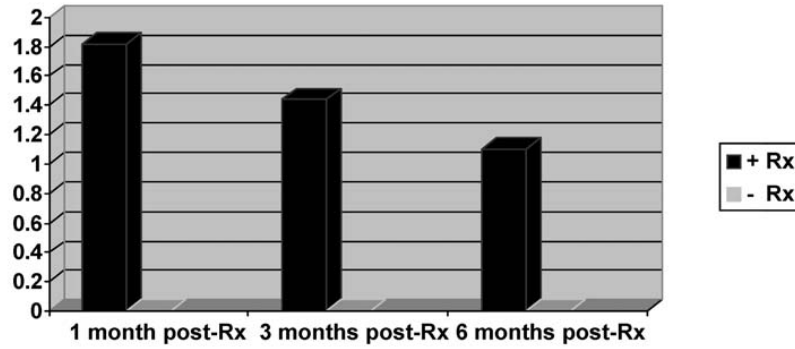
Results

All 20 patients completed the 7-month study. All but two patients noticed overall improvement in cellulite in the treated thigh/buttock regions based on subjective questionnaires. Seventeen of these 18 patients reported that they would undergo treatment on the contralateral thigh. The one patient who would not pursue additional treatment had experienced bruising with the initial sessions. Side effects were limited to transient erythema in most patients (average duration <1 hour). Bruising was observed in 10% (2/20) of study participants after the first couple of treatment sessions, but in no patient as the treatment series progressed. Treatment was well tolerated with minimal to no discomfort — the sensation most often described as “mild heating” with occasional “pinching”.

Clinical improvement scores averaged 1.82 (corresponding to approximately 50% improvement) one month after the series of treatments. Slight diminution of clinical effect was noted at the three- and six-month follow-up evaluations (Figures 1, 2A and B, 3A and B). Circumferential thigh measurements were reduced by 0.8 cm on the treatment side (Figure 4). There were no measurable differences in the non-treated thighs nor in total body weight (average baseline weight = 148.3 lbs, post-Rx weight = 148.0 lbs) at end-study. 2

Discussion

Cellulite remains a concern of an estimated 85% of post-pubertal women who will go to great lengths and expense to find a worthwhile treatment. Most topical treatments that have been touted as effective cellulite reducers contain caffeine and marine

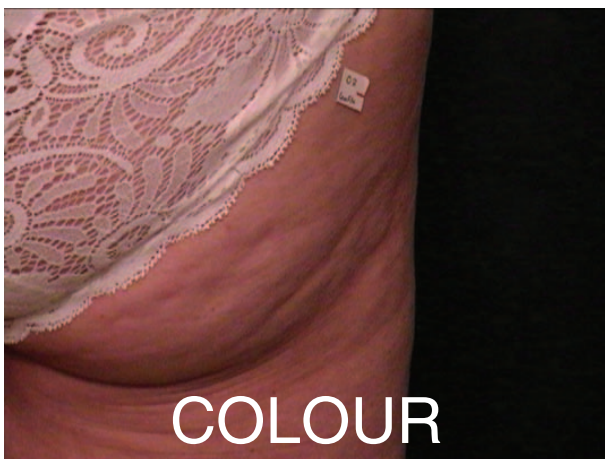


Grading: 0 = <25%, 1 = 25%--50%, 2 = 51%--75%, 3 = >75% improvement

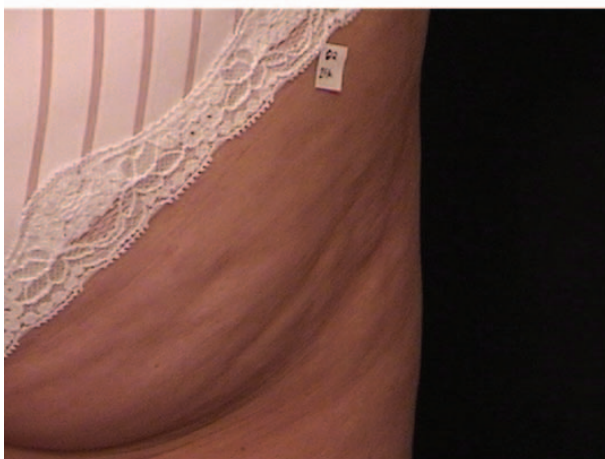Figure 1. Clinical improvement scores.

extracts that serve to temporarily dehydrate fat cells, making them appear smaller (10)(11)(12)(13). The water that is drawn into the surrounding skin by simple hydration may additionally give the skin a firmer appearance. Various herbal ingredients (e.g., black pepper, ginger, green tea, capsicum, cinnamon) have been popularized due to their ability to stimulate microvascular flow (14). Retinol has been

shown to keep fat cells from maturing in laboratory tests (15). The biggest drawback to topical cellulite treatments is their inability to significantly penetrate skin in order to render more than a transient (and superficial) tissue effect. The concomitant use of occlusive garments has been shown to enhance the penetration (and perhaps potentiate the effect) of topical agents, but again, the results appear limited




(A)

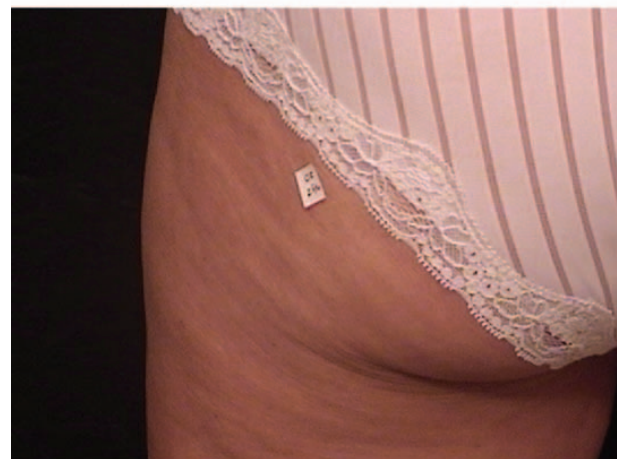


(B)

Figure 2A. Cellulite before treatment. Figure 2B. Six months after eight VelaSmooth treatments (clinical improvement score: 1).



(A)



(B)

Figure 3A. Cellulite at baseline. Figure 3B. No change noted (untreated side). Score = 0.

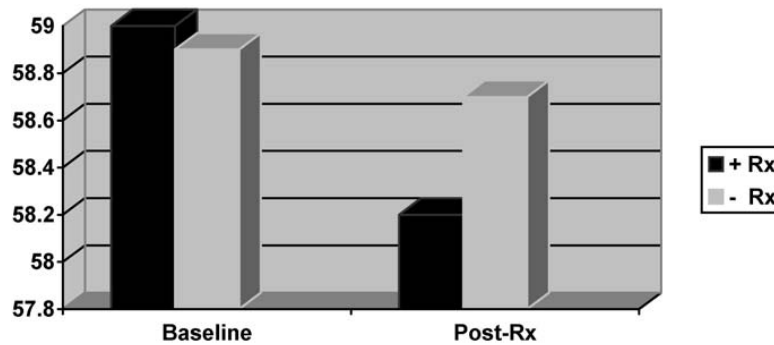


Figure 4. Thigh measurements (in centimeters).

and temporary (14).

Noninvasive massage therapies, including suction-based mechanical massage units such as Endermologie in which motorized rollers on either side of a vacuum chamber produce up to 500 mbar of low pressure, have been studied with variable results (16). Endermologie's efficacy in improving cellulite is believed to result from stretching of the vertical connective tissue and stimulation of lymphatic flow as a result of the extreme pressure difference and the rolling motion dictated by the technique. Collis and colleagues studied the effects of aminophylline cream and Endermologie alone, and in combination, for thigh and buttock cellulite, and determined that no statistical difference existed in leg measurements in any treatment group (17). Subjective assessments revealed slightly better response to the Endermologie-treated legs than to the aminophylline-treated legs, but the authors were unconvinced as to the efficacy of either treatment.

Dietary supplements containing cellasene, ginkgo biloba, sweet clover, and grape seed have been touted to increase metabolism and circulation while decreasing swelling, but are not FDA-approved as cellulite treatments. In addition, cellasene contains significant levels of iodine and therefore should be avoided by those individuals with thyroid conditions.

Surgical subcision has been noted to improve moderate to severe cellulite (18). The technique involves the insertion of a needle to interrupt the connective tissue adhesions that tether the dermis to the underlying fascia, thereby diminishing the lumpy skin appearance. The longevity of clinical effect remains unclear. Liposculpture has also been used to decrease the appearance of cellulite by reducing local fat volume and by disrupting the fibrous bands, but again, long-term results are lacking.

Mesotherapy is yet another popularized treatment for cellulite, despite few studies substantiating its effectiveness and longevity (19),(20). The technique involves a series of injections that perfuse a variety of liquid preparations into the subcutis. The solutions have included such compounds as aminophylline, hormones, enzymes, herbal extracts, vitamins, and minerals, but the one ingredient most consistently used is a soybean lecithin extract (phosphatidylcholine) that

is responsible for lipolysis. The lack of a precise treatment protocol and the risk of localized adverse events, including edema, ecchymoses, tender subcutaneous nodules, infection, urticarial reactions, and irregular skin contours, led to banning of phosphatidylcholine by the Brazilian National Agency of Health in 2003. Its use in the US has yet to be approved by the FDA.

The study reported herein demonstrates one of the latest noninvasive treatments for cellulite and involves a combination of mechanical massage which improves microcirculation and concomitant radiofrequency and infrared light heat delivery to the dermis which can initiate collagen remodeling through controlled tissue inflammation and collagen contraction. No significant side effects were observed and patients tolerated the treatment sessions without difficulty. The fact that clinical results remained in evidence for several months after the series of eight sessions attests to the longevity of the treatment. However, in practice, it would seem reasonable to continue maintenance treatments on a monthly basis in order to further enhance the results obtained.

One could argue that any treatment that makes the skin thicker and more reflective can reduce the appearance of cellulite. The use of topical creams that tighten, moisturize, and attempt to thicken the epidermis thus have been shown to improve the clinical appearance of cellulite, albeit temporarily. Combined technologic advances, such as demonstrated by the device in this study, serve to add even further clinical improvement, as well as longevity to the results obtained. The negative pressure massage serves to improve circulation and loosen the bands of connective tissue around the fat deposits that cause skin dimpling, while the radiofrequency and infrared energy heat the skin, creating a controlled inflammatory response and rendering it more malleable and receptive to the rolling action of the massage unit. Lymphatic drainage is thus enhanced creating reduced tissue bulk and dimpling.

The nonpermanence of clinical effects obtained should not overshadow the positive aspects of the treatment modality as a whole. The combined radiofrequency, infrared light, and suction-based

massage technology has been shown to be a safe and effective treatment option with long-lasting results. Maintenance treatments may extend and further improve upon the results obtained.

Conclusions

Cellulite can be significantly and safely reduced with the use of a noninvasive device that combines bipolar RF, infrared light, and mechanical massage. The effects of treatment appear to be prolonged, but maintenance treatments may be necessary to further enhance the clinical results achieved.

References

1. Guyton AC, Hall JE. Textbook of Medical Physiology. 9th ed. Philadelphia: WB Saunders; 1996.
2. Rees T, LaTrenta G. Aesthetic Plastic Surgery, Vol II. 2nd ed. Philadelphia: WB Saunders; 1994: p 1187.
3. Karnielli E. Glucose transport in rat and human adipose tissue. In: Illouz YG, Devillers YT, editors. Body Sculpturing by Lipoplasty. Edinburgh: Churchill Livingstone; 1988. p 457–67.
4. Kligman AM. Cellulite: facts and fiction. *J Geriatr Dermatol.* 1997;5:136–9.
5. Curri SB. Cellulite and fatty tissue microcirculation. *Cosmet Toilet.* 1993;108:51–8.
6. Leibaschoff GH. Cellulite (liposclerosis): etiology and treatment. *Am J Cosmet Surg.* 1997;14:395–401.
7. Goldman MP. Cellulite: a review of current treatments. *Cosmet Dermatol.* 2002;15:17–20.
8. Alster TS, Doshi S. Ablative and non-ablative laser skin resurfacing. In: Burgess C, editor. *Cosmetic Dermatology.* Heidelberg: Springer-Verlag; 2005. p 111–26.
9. Alster TS, Tanzi EL. Improvement of neck and cheek laxity with a non-ablative radiofrequency device: a lifting experience. *Dermatol Surg.* 2004;30:503–07.
10. Buscaglia DA, Conte ET. The treatment of cellulite with methylxanthine and herbal extract based cream: an ultrasonographic analysis. *Cosmet Dermatol.* 1996;9:30–40.
11. Lesser T, Ritvo E, Moy LS. Modification of subcutaneous adipose tissue by a methylxanthine formulation: a double-blind controlled study. *Dermatol Surg.* 1999;25:455–62.
12. Jackson EM. Substantiating the efficacy of thigh creams. *Cosmet Dermatol.* 1995;8:31–41.
13. Dickinson BI, Gora-Harper ML. Aminophylline for cellulite removal. *Ann Pharmacother.* 1996;30:292–3.
14. Rao J, Paabo KE, Goldman MP. A double-blinded randomized trial testing the tolerability and efficacy of a novel topical agent with and without occlusion for the treatment of cellulite: a study and review of the literature. *J Drugs Dermatol.* 2004;3:417–25.
15. Kligman AM, Pagnoni A, Stoudemayer T. Topical retinol improves cellulite. *J Dermatol Treat.* 1999;10:119–25.
16. Chang P, Wiseman J, Jacoby T, Salisbury AV, Ersek RA. Noninvasive mechanical body contouring (Endermologie): a one-year clinical outcome study update. *Aesthetic Plast Surg.* 1998;22:145–53.
17. Collis N, Elliot LE, Sharpe C, Sharpe DT. Cellulite treatment: a myth or reality: a prospective randomized, controlled trial of two therapies, Endermologie and aminophylline cream. *Plast Reconstr Surg.* 1999;104:1110–17.
18. Hexsel DM, Mazzuco R. Subcision: a treatment for cellulite. *Int J Dermatol.* 2000;39:539–44.
19. Rotunda AM, Suzuki H, Moy RL, Kolodney MS. Detergent effects of sodium deoxycholate are a major feature of an injectable phosphatidylcholine formulation used for localized fat dissolution. *Dermatol Surg.* 2004;30:1001–09.
20. Hexsel D, Serra M, Mazzuco R, Dal'Forno T, Zechmeister D. Phosphatidylcholine in the treatment of localized fat. *J Drugs Dermatol.* 2003;2:511–18.

3